Neurosurg Focus 25 (2):E4, 2008

Minimally invasive anterior vertebroplasty for C-2 metastatic lesions

Technical note

Richard Rhiew, M.D., Ph.D., Sunil Manjila, M.D., Adam DeZure, B.S., Monir Tabbosha, M.D., Murali Guthikonda, M.D., and Hazem Eltahawy, M.D., Ph.D.

Department of Neurological Surgery, Wayne State University, Detroit, Michigan

The authors describe a technique for minimally invasive anterior vertebroplasty for treating metastatic disease of the C-2 vertebra and discuss its application in 2 cases. After a 2-cm lateral neck incision is made, blunt dissection is performed toward the anterior inferior endplate of the C-2 vertebra. An 11-gauge needle is introduced through a tubular sheath and tapped into the inferior endplate of C-2, with biplanar fluoroscopy being performed to confirm position. The needle is subsequently advanced across the fracture line and into the odontoid process. Under fluoroscopic guidance, 2 ml of methylmethacrylate is injected into the odontoid process and vertebral body. This method is advantageous as 1) hyperextension of the neck is not performed, 2) the chance of inadvertent neurovascular or submandibular gland injury is minimized, 3) the possibility of cement leakage is decreased, and 4) hemostasis is better achieved under direct vision. *(DOI: 10.3171/FOC/2008/25/8/E4)*

Key Words • **compression fracture** • **minimally invasive surgery** • **pathological fracture** • **vertebroplasty**

Percutaneous vertebroplasty enables minimally invasive treatment of both vertebral tumors and compression fractures of the cervical spine. The injection of radiopaque cement across a cervical spine fracture increases the strength and stiffness of the VB and has been shown to provide pain control in up to 90% of patients.[20,21,23,30] Both anterolateral and transoral approaches have been successfully implemented for the treatment of metastatic lesions in the upper cervical spine.[8,15,16,28,29] While efficacious, both approaches carry potentially life-threatening complications. The anterolateral approach entails guiding a 14-gauge beveled needle under fluoroscopic guidance through the parapharyngeal, retropharyngeal, and prevertebral spaces before reaching the C-2 VB. The risks of the procedure include damage to important blood vessels (internal jugular vein, vertebral and carotid arteries) and nerves (vagal, spinal, accessory, lingual, hypoglossal, marginal mandibular, and laryngeal), as well as the submandibular gland. The transoral approach to C-2 vertebroplasty minimizes the risk of neurovascular complication with a more direct route through the posterior oropharyngeal wall under fluoroscopic guidance into the VB of C-2. The direct transoral route, however, carries the an increased risk of infectious complications, including pharyngeal wound breakdown, meningitis, and encephalomeningitis, that could be devastating to patients with limited immune reserves.[18,27] Transoral surgery can only be performed with the patient in a state of general anesthesia, often requiring difficult tracheal intubation with manual cervical stabilization or fiberoptic intubation, which limits its use in patients whose general clinical condition is poor.[1,18,24,26,27] Furthermore, wound healing is critically important in patients with C-2 metastatic lesions who may be at increased risk should they require focal radiation therapy after transoral surgery. To circumvent these complications, we investigated a novel minimally invasive anterior approach for performing C-2 vertebroplasty.

Surgical Technique

General anesthesia is induced and an endotracheal tube is placed. The patient's neck is oriented in a neutral position. Fluoroscopy is used to identify and demarcate the level of C-4, and the skin on the lateral neck is opened through a 2-cm incision (Fig. 1). The platysma is opened with monopolar cautery and the cervical fascia is opened under direct visualization. While the submandibular gland is manually protected, blunt finger dissection is performed—using lead gloves—down the avascular plane between the carotid sheath laterally and the trachea, esophagus, and hypopharynx medially. Fluoroscopy enables blunt dissection superiorly and obliquely towards the anterior inferior endplate of C-2 (Fig. 2A). Once the C2–3 disc space is

Abbreviation used in this paper: VAS = visual analog scale; VB = vertebral body.

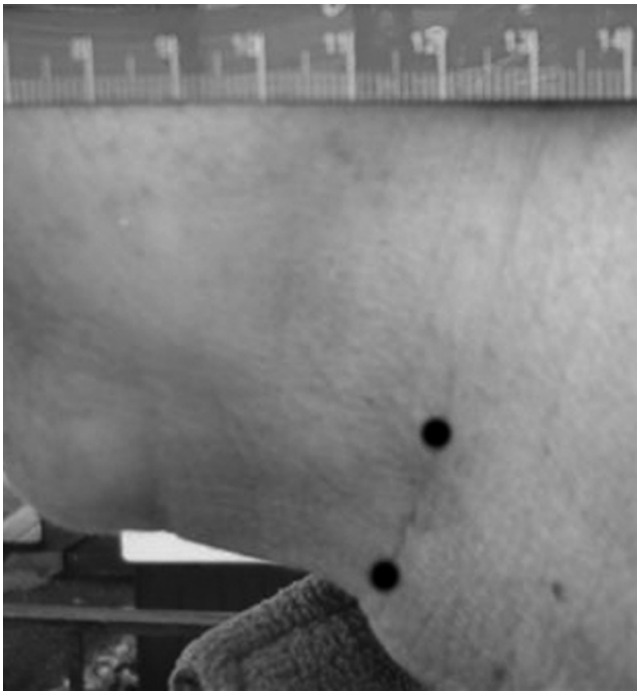

FIG. 1. Photograph showing the site of the incision on the lateral neck. A 2-cm incision is made along a skin crease, using fluoroscopy to identify and demarcate the level of C-4.

reached, a blunt Penfield #2 dissector guided by the lead-gloved finger, is anchored. Onto this dissector, a plastic tubular sheath is introduced to prevent soft tissue damage. The tubular sheath is tucked onto the lower anterior margin of the C-2 VB. The Penfield dissector is then removed. An 11-gauge Stryker vertebroplasty needle is introduced through the sheath and tapped into the inferior endplate of C-2; biplanar fluoroscopy is performed to confirm position. The needle is then advanced across the fracture line and into the odontoid process. Under fluoroscopic guidance, 2 ml of methylmethacrylate is injected, filling the odontoid process and the VB (Fig. 2B). The needle is removed and the wound is irrigated with antibiotic solution. The wound is closed with 4-0 Vicryl.

Illustrative Cases

This method of minimally invasive anterior vertebroplasty was applied in 2 cases involving patients presenting with metastatic lesions of the C-2 VB.

Case 1

History and Presentation. This 79-year-old woman presented with recurrent breast cancer and a metastatic lesion involving the odontoid process and the VB of C-2 (Fig. 3A-D). A CT scan revealed a hairline fracture across the diseased odontoid process. The patient complained of severe intractable neck pain of 3 weeks' duration, with a VAS score of 9. She was treated conservatively with opioid analgesic agents and her neck was immobilized with a hard cervical collar.

First Operation. Given the presence of continued pain and a significant osteolytic lesion, it was decided to stabilize the patient's spine surgically. A minimally invasive approach was selected because of the patient's age and her history of recurrent breast disease as well as the presence of additional spine lesions. In this initial procedure, 2 ml of

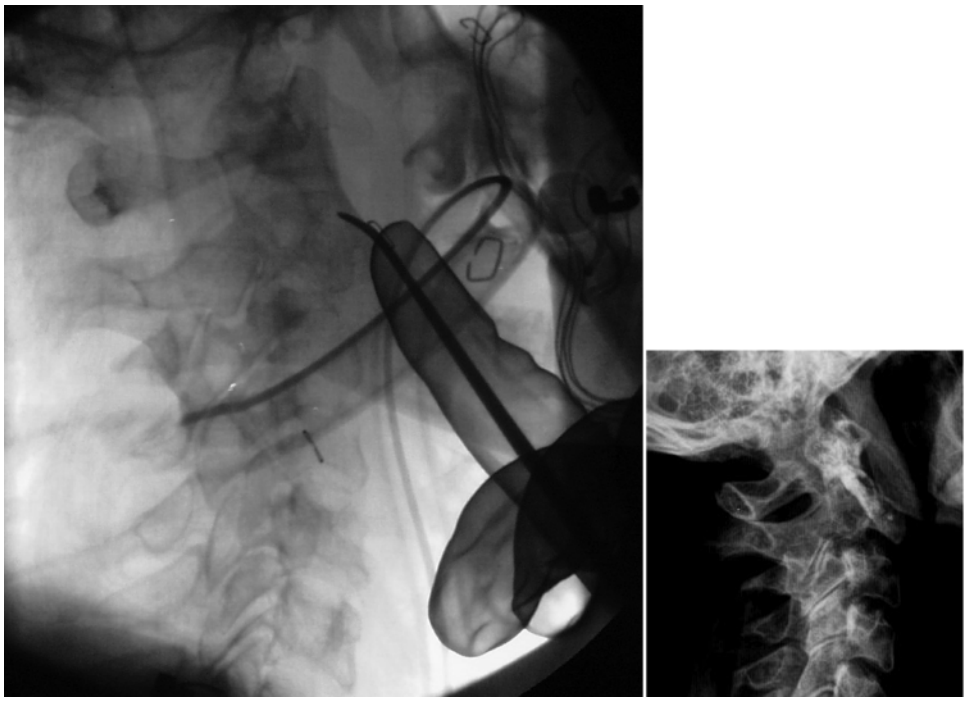

FIG. 2. A: Intraoperative lateral fluoroscopic image illustrating minimally invasive C-2 vertebroplasty performed with finger dissection using a lead glove via a 2-cm incision. B: Postoperative radiograph showing cement filling the lesion following C-2 vertebroplasty.

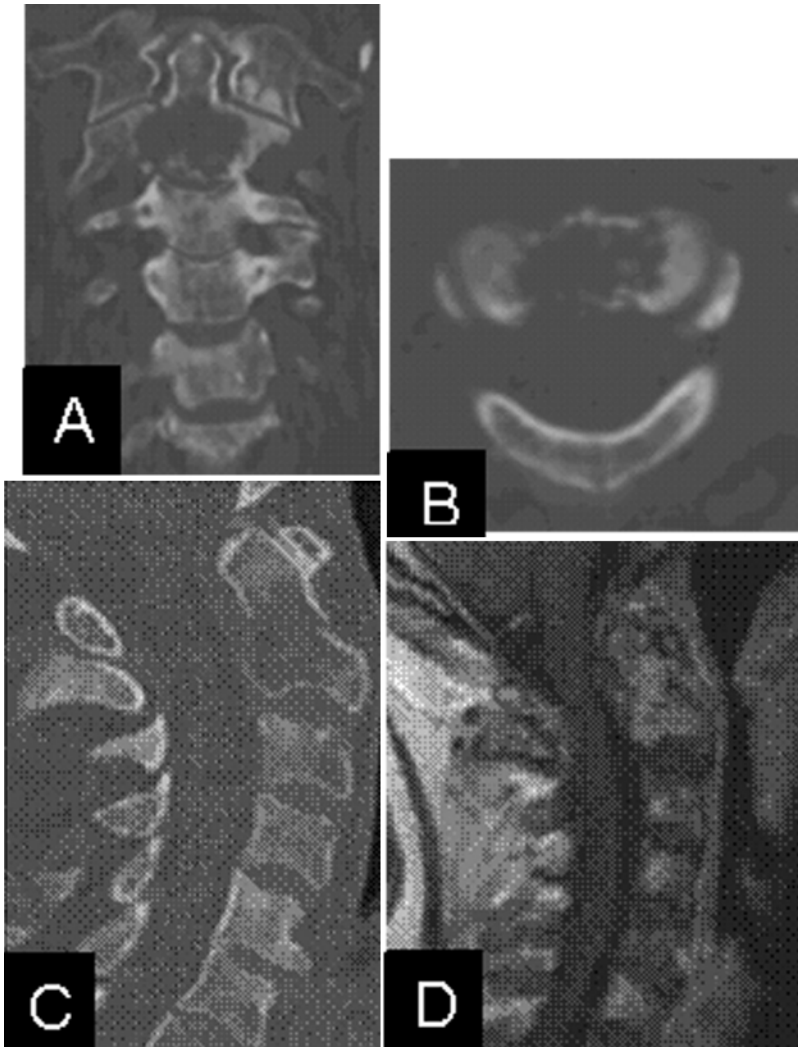

FIG. 3. Preoperative CT (A-C) and MR imaging (D). A: Coronal reconstruction showing a C-2 pathological fracture. B: Axial scan showing a C-2 pathological fracture. C: Sagittal reconstruction showing a C-2 pathological fracture. D: Sagittal Gd-enhanced T1-weighted MR image showing an enhancing C-2 pathological fracture.

methylmethacrylate was injected across the fracture, but technical factors resulted in poor visualization of the injected cement with fluoroscopy and the procedure was aborted due to considerations for the patient's safety.

Second Operation. Based on a postoperative CT scan, the amount of stabilization was felt to be inadequate. A decision was made to bring the patient back for a second operation for further fixation of the fracture using the minimally invasive anterior approach. This second procedure was performed approximately 12 hours after the first.

An 11-gauge needle was introduced into the C-2 VB under fluoroscopic guidance until the previously injected cement was reached. An additional 2 cm of methylmethacrylate was introduced. The injection was stopped, and minimal extravasation of cement noted anterior to the odontoid process. The patient stayed in the hospital for 1 day after this procedure.

Follow-Up. Clinical follow-up at 6 months reveals a patient with much improved pain and neurological stability. She is driving her car without the need for a cervical collar and has completed palliative external beam radiation therapy to her cervical spine. She is off narcotic medication with a VAS score of 0.

Case 2

History and Presentation. This 54-year-old woman presented with Stage 4 breast cancer and metastases to liver, lung, and bone. She was being treated with an opioid pain patch for intractable metastatic pain (VAS score 9) and was considering hospice care.

Operation and Postoperative Course. Minimally invasive anterior C-2 vertebroplasty was chosen due to the findings of a Type 3 fracture at the base of the odontoid process and an extensively lytic metastatic lesion in the C-2 VB. During the procedure, 50% filling of the odontoid process was achieved, with lesser filling of the osteolytic area of the C-2 VB. She was discharged 4 days following the surgery

with remarkable improvement in her neck pain. A hard collar was recommended for comfort.

Follow-Up. Clinical follow-up at 4 months revealed the patient to be without neck pain (VAS score 0), completely independent in her activities of daily living, and in excellent spirits following her procedure. She continues to follow a regimen of narcotic medication, however, for pain from her multiple metastases.

Discussion

Bone is the second most common site for cancer metastasis. Secondary spine lesions are found in 30% of patients with cancer.[20] Percutaneous C-2 vertebroplasty is a challenging technique that can be performed for upper cervical spine metastases.[18,20,24,26,27] This procedure helps to achieve quick pain control and maintain spinal stability while preventing vertebral collapse and neurological deterioration from spinal cord compression. A minimally invasive procedure that is well tolerated and associated with a low morbidity rate, it substantially increases the strength and stiffness of the VB.[19] The analgesia offered by vertebroplasty results from reduced micromotion as well as increased strength of the VB. Other hypotheses for the analgesic effects of percutaneous vertebroplasty include the destruction of nerve endings by the exothermic reaction occurring during polymerization and an inherent tumoricidal or cytotoxic effect of methylmethacrylate. Vertebroplasty is frequently used as an adjunct to surgery and radiation therapy or in association with systemic chemotherapy (hormone therapy, chemotherapy, or radioactive iodide therapy).[3,14,20,26] Percutaneous vertebroplasty has been performed in the thoracolumbar spine, but not the cervical spine, via a transpedicular approach. Before vertebroplasty is performed in the cervical spine, the height and width of the targeted C-2 pedicle should be measured to ensure that it is at least 5 mm in each dimension.[17] A size of < 5 mm in each dimension has been reported to lead to increased risk of vertebral artery injury in the placement of 3.5-mm screws through the C-2 isthmus.[17] A transpedicular approach is thus risky in the C-2 vertebra because of small cervical pedicles and the potential risk of vertebral artery injury. A paravertebral approach in the cervical region can injure adjacent neural and vascular structures. Furthermore, the axis is a crucial part of a complex biomechanical system which participates in flexion, extension, rotation, lateral bending, and axial loading as well as distraction.[14,20,25] Hence, arthrodesis or fixation may not be clinically acceptable due to restricted range of motion. Percutaneous vertebroplasty allows the option of preserving the mobility of the upper cervical spine, although surgical stabilization is required if vertebroplasty fails to provide sufficient stability.[9] In minimally invasive C-2 vertebroplasty, the trajectory and location of the entry point relative to the vertebra to be treated differ from those used in vertebroplasty of the thoracolumbar spine. Our proposed minimally invasive surgical technique entails a trajectory far different from the standard transpedicular route. This ensures a maximum distance between the site of cement injection and the entry point of the needle into the bone, thereby reducing the risk of soft tissue cement leak along the needle track.

Anatomically, the transoral route provides the most direct access to the C-2 VB.[24] There are anecdotal reports of cases in which the posterior oropharynx was accessed by elevating the soft palate using a Foley catheter passed through the nasopharynx and sutured to the uvula or by straightening the uvula using the vertebroplasty needle covered by a sterile plastic bag.[18,27] Compared to open surgery, vertebroplasty offers a minimally invasive treatment for metastatic lesions in the C-2 VB. Controlled direct needle insertion using biplanar fluoroscopy minimizes needle excursion and the risk of neurovascular complication.[12,13,15,16,19] Transoral vertebroplasty is reported to be associated with lower infection rates than transoral surgery, given minimal disruption of the posterior oropharyngeal tissues by the needle.[24] Thin puncture needles, short operation time, and mixing tobramycin with methylmethacrylate have contributed to low infection rates with vertebroplasty. As in patients with aneurysmal bone cysts, hemangiomas, myelomas, and fibrous dysplasias, transoral vertebroplasty has been reported to alleviate cervical pain in patients with osteoporotic fractures and osteolytic metastases in a rapid and durable manner.[5,6,10,25–27]

The anterolateral approach for upper cervical spine vertebroplasty has gained popularity because it can be performed without general anesthesia or endotracheal intubation. The anterolateral route entails less risk of infection as the needle does not traverse the oral cavity. The anterolateral approach requires manual retraction of the carotid artery and jugular vein with placement of the needle between the vessels, the pharynx and the larynx. The needle path originates below the mandible ascending in the medial direction. This approach places several anatomical structures at risk including the vagal, spinal accessory, lingual, hypoglossal, marginal mandibular, and laryngeal nerves, in addition to the internal jugular vein and the vertebral and carotid arteries.[24] A percutaneous inferior anterolateral approach with the needle placed under the mandible and then directed cephalad and anteromedially is particularly difficult and risky.[8,20,27]

The minimally invasive surgical technique presented in this paper allows vertebroplasty to be performed under direct vision, thereby avoiding complications such as neurovascular and submandibular gland injury, with a lower chance of cement leakage through the entry site.[25] This procedure would facilitate adequate bone biopsy and has the advantage of minimizing intraprocedural hyperextension of the spine. Hemostasis, which is critically important for airway protection, is easier to achieve in potentially bleeding metastatic bone with the minimally invasive surgical technique presented in this paper than with a closed percutaneous procedure.

In a large series of 289 VB injections, Gangi et al. reported a satisfactory outcome (reduction in analgesic dose) in 78% of patients with osteoporotic fractures, 83% of patients with metastatic lesions, and 73% of patients with aggressive vertebral hemangiomas.[11,13] Age of the fracture as determined by onset of symptoms was not a predictor of success.[13] Complications, including epidural cement leak causing neuralgia, rib and pedicle fractures, cement pulmonary embolism, and foraminal venous leak into intercostal arteries are described in various reports of vertebroplasty.[2,21–23]

There are not many published reports of C-2 vertebro-

TABLE 1

Summary of relevant C-2 vertebroplasty publications

Authors & Year	No. of Patients	Approach	Anesthesia
Tong et al., 2000	1	transoral	general
Martin et al., 2002	1	transoral	general
Gailloud et al., 2002	1	transoral	general
Mont'Alverne et al., 2005	12	percutaneous	conscious sedation
Rodrigues-Catarino et al., 2007	1	percutaneous	conscious sedation

plasty in the existing neurosurgical literature. Table 1 reviews the most often cited publications. Mont'Alverne et al.[20] reported a case series of 12 patients undergoing percutaneous vertebroplasty between 1994–2004; this report represents the largest study of C-2 vertebroplasty to date. Pain relief was reported in 80% of patients and stability in 87.5%. Apart from asymptomatic cement leaks, recognized complications of the anterolateral approach include occipital neuralgia and ischemic stroke. The limitation of this technique is that hyperextension of the neck is needed for the anterolateral approach. In patients in whom cervical hyperextension is not feasible, such as those with severe vertebral collapse, needle insertion becomes extremely difficult.[20] The minimally invasive anterior approach that we propose in this paper does not require hyperextension of the neck to gain access to the C-2 vertebra.

There are case reports of adjacent vertebrae being treated with percutaneous vertebroplasty using a Seldinger technique in patients in whom the lesion involves the C2-3 VBs. Intraosseous venography is used to assess for extravasation into the spinal canal. The transpedicular approach is performed utilizing a left posterolateral trajectory under image guidance through hypertrophic diseased bone in polyostotic fibrous dysplasia.[4,7,25] Likewise, there are anecdotal reports of cases in which percutaneous vertebroplasty was performed for a traumatic C-2 VB fracture.[1] Nevertheless, there is still controversy in performing vertebroplasty in cases in which the VB height is less than one-third of normal or the posterior wall is destroyed, thereby increasing the risk of cement extrusion into the canal.[30]

Although we believe that the chance of neurovascular injury is decreased with our method of minimally invasive surgical treatment, contraindications for vertebroplasty documented in the literature apply to C-2 lesions as well as thoracolumbar lesions. Absolute contraindications include overt infection in tissue through which the needle must pass and preexisting epidural metastatic tumor with encroachment on neurovascular structures causing myeloradiculopathy.[20] Relative contraindications include severe loss of height (loss > 70% being associated with poor likelihood of good outcome) and coagulopathy or cardiorespiratory compromise such that safe sedation or anesthesia cannot be achieved. Open surgical intervention is recommended for patients with significant neural compression or spinal instability.[13]

Conclusions

We describe a minimally invasive C2 vertebroplasty technique as a safe and effective option in the treatment armamentarium for patients with metastatic involvement of the C-2 vertebra, especially when aggressive surgical treatment is unwarranted. This minimally invasive technique should entail a lower risk of injuring neighboring structures than the percutaneous alternative. This novel technique is expected to benefit those patients with relatively limited life expectancy, whose treatment is more palliative than curative, or in whom a long open surgical procedure would be contraindicated due to systemic comorbidities.

Disclaimer

The authors do not report any conflict of interest concerning the materials or methods used in this study or the findings specified in this paper.

References

1. Anselmetti GC, Regge D, Sardo E, Manca A, Cirillo S, Meloni T, et al: Minimally invasive treatment of C2 odontoid traumatic fracture with transoral percutaneous vertebroplasty. **Eur Radiol 17:**850–851, 2007
2. Barragán-Campos HM, Vallée JN, Lo D, Cormier E, Jean B, Rose M, et al: Percutaneous vertebroplasty for spinal metastases: complications. **Radiology 238:**354–362, 2006
3. Casasco A, Houdart E, Biondi A, Jhaveri HS, Herbreteau D, Aymard A, et al: Major complications of percutaneous embolization of skull-base tumors. **AJNR Am J Neuroradiol 20:**179–181, 1999
4. Christoforidis G, Dang D, Gabriel J: Catheter-directed percutaneous transpedicular C2/C3 vertebroplasty in a patient with fibrous dysplasia using Seldinger technique **AJNR Am J Neuroradiol 27:**1738–40, 2006
5. Cortet B, Cotton A, Boutry N, Dewatre F, Flipo RM, Duquesnoy B, et al: Percutaneous vertebroplasty in patients with osteolytic metastases or multiple myeloma. **Rev Rhum Engl Ed 64:**177–183, 1997
6. Cotten A, Dewatre F, Cortet B, Assaker R, Leblond D, Duquesnoy B, et al: Percutaneous vertebroplasty for osteolytic metastases and myeloma: effects of the percentage of lesion filling and the leakage of methyl methacrylate at clinical follow-up. **Radiology 200:**525–530, 1996
7. Dang D, Baig MN, Christoforidis G, Chiocca EA, Gabriel J: C2/C3 pathologic fractures from polyostotic fibrous dysplasia of the cervical spine treated with percutaneous vertebroplasty. **Eur Spine J 3 (16 Suppl):**250–254, 2007
8. Dufresne AC, Brunet E, Sola-Martinez MT, Rose M, Chiras J: [Percutaneous vertebroplasty of the cervico-thoracic junction using an anterior route. Technique and results. Report of nine cases.] **J Neuroradiol 25:**123–128, 1998
9. Fourney DR, York JE, Cohen ZR, Suki D, Rhines LD, Gokaslan ZI: Management of atlantoaxial metastases with posterior occipitocervical stabilization. **J Neurosurg 93 (2 Suppl):**165–170, 2003
10. Gailloud P, Martin JB, Olivi A, Rüfenacht DA, Murphy KJ: Transoral vertebroplasty for a fractured C2 aneurysmal bone cyst. **J Vasc Inter Radiol 13:**340–341, 2002
11. Gangi A, Dietemann JL, Guth S, Steib JP, Roy C: Computed tomography (CT) and fluoroscopy-guided vertebroplasty: results and complications in 187 patients. **Sem Intervent Radiol 16:**137–142, 1999
12. Guglielmi G, Andruela C, Muto M, Gilula LA: Percutaneous vertebroplasty: indications, contraindications, technique and complications. **Acta Radiol 46:**256–268, 2005
13. Hide IG, Gangi A: Percutaneous vertebroplasty: history, technique and current perspectives. **Clin Radiol 59:**461–467, 2004
14. Jenis LG, Dunn EJ, An HS: Metastatic disease of the cervical spine. A review. **Clin Orthop Relat Res 359:**89–103, 1999

15. Jensen ME, Evans AJ, Mathis JM, Kallmes DF, Cloft HJ, Dion JE: Percutaneous polymethylmethacrylate vertebroplasty in the treatment of osteoporotic vertebral body compression fractures: technical aspects. **AJNR Am J Neuroradiol 18:**1897–1904, 1997
16. Levine SA, Perin LA, Hayes D, Hayes WS: An evidence-based evaluation of percutaneous vertebroplasty. **Manag Care 9:**56–60, 2000
17. Mandel IM, Kambach BJ, Petersildge CA, Johnstone B, Yoo JU: Morphologic considerations of C2 isthmus dimensions for the placement of transarticular screws. **Spine 25:**1542–1547, 2000
18. Martin JB, Gailloud P, Dietrich PY, Luciani ME, Somon T, Sappino PA, et al: Direct transoral approach to C2 for percutaneous vertebroplasty. **Cardiovasc Intervent Radiol 25:**517–519, 2002
19. Molloy S, Mathis JM, Belkoff SM: The effect of vertebral body percentage fill on mechanical behavior during percutaneous vertebroplasty. **Spine 28:**1549–1554, 2003
20. Mont'Alverne F, Vallée JN, Cormier E, Guillevin R, Barragan H, Jean B, et al: Percutaneous vertebroplasty for metastatic involvement of the axis. **AJNR Am J Neuroradiol 26:**1641–1645, 2005
21. Murphy KJ, Deramond H: Percutaneous vertebroplasty in benign and malignant disease. **Neuroimaging Clin N Am 10:**535–545, 2000
22. O' Brien JP, Sims JT, Evand AJ: Vertebroplasty in patients with severe vertebral compression fractures: a technical report. **AJNR Am J Neuroradiol 21:**1555–1558, 2000
23. Pilitisis JG, Rengachary SS: The role of vertebroplasty in metastatic spinal disease. **Neurosurg Focus 11(6):**E9, 2001
24. Reddy AS, Hochman M, Loh S, Rachlin J, Li J, Hirsch JA: CT guided direct transoral approach to C2 for percutaneous vertebroplasty. **Pain Physician 8:**235–238, 2005
25. Rodriguez-Catarino M, Blimark C, Willén J, Mellqvist UH, Rödjer S: Percutaneous vertebroplasty at C2: case report of a patient with multiple myeloma and a literature review. **Eur Spine J 16 (3 Suppl):**242–249, 2007
26. Sachs DC, Inamasu J, Mendel EE, Guiot BH: Transoral vertebroplasty for renal cell metastasis involving the axis: case report. **Spine 31:**E925–E928, 2006
27. Tong FC, Cloft HJ, Joseph GJ, Rodts GR, Dion JE: Transoral approach of cervical vertebroplasty for multiple myeloma. **AJR Am J Radiol 175:**1322–1324, 2000
28. Vender JR, McDonnell DE: Management of lesions involving the craniovertebral junction. **Neurosurg Quarterly 11:**151–171, 2001
29. Vieweg U, Meyer B, Schramm J: Tumour surgery of the upper cervical spine—a retrospective study of 13 cases. **Acta Neurochir (Wien) 143:**217–225, 2001
30. Weill A, Chiras J, Simon JM, Rose M, Sola-Martinez T, Enkaoua E: Spinal metastases: indications for and results of percutaneous injection of acrylic surgical cement. **Radiology 199:**241–247, 1996

Manuscript submitted May 15, 2008.
Accepted June 2, 2008.
Address correspondence to: Hazem Eltahawy, M.D., Ph.D., Department of Neurosurgery, Wayne State University, 4201 St. Antoine, UHC 6E, Detroit, Michigan 48201. email: heltahawy@med.wayne.edu.